

Sonographic Evaluation of the Pancreas in Type 1 Diabetes Mellitus: A Case-control Study

Safa Abdulrahman¹, Ahmed Abdelrahim Ibrahim¹, Mohamed Adam Mohamed^{2*}, Moawia Gameraddin³, Magbool Alelyani²

¹Department of Diagnostic Radiology, Faculty of Radiological Sciences and Medical Imaging, Alzaieem Alazhari University, Khartoum, Sudan, ²Department of Radiological Sciences, College of Applied Medical Sciences, King Khalid University, Abha, Saudi Arabia, ³Department of Diagnostic Radiologic Technology, Faculty of Applied Medical Sciences, Taibah University, Medina, Saudi Arabia

Abstract

Background: Pancreas is a vital insulin-producing gland, and it is subjected to various disorders which produce alteration in the morphology and function. Ultrasound (US) of the pancreas is sensitive for evaluating the gland and provides the accurate diagnosis of pancreatic diseases. The aim of this study is to determine whether there were alterations in pancreatic size and echogenicity in type 1 diabetes mellitus (DM). **Methods:** A total of 100 patients with Type-1 DM (insulin dependent) were examined using the ultrasonography. They were compared to 22 healthy controls. Measurements of the pancreas were performed on type 1 diabetic patients and controls. **Results:** Pancreatic diameters of the head, body, and tail of the pancreas were reduced in Type 1 DM versus controls (1.78 vs. 1.80 cm, 95% confidence interval [CI]: -0.147 -0.099, $P = 0.699$ for the head of the pancreas; and 1.093 vs. 1.13 cm: 95% CI: -2.97-1.196, $P = 0.484$ for the body of the pancreas; 1.12 vs. 1.46 cm, 95% CI: -0.491-0.194, $P < 0.001$ for the tail of the pancreas). The echogenicity of the pancreas in patients with Type 1 DM increased significantly as the duration of the disease increased ($P = 0.015$). **Conclusion:** Individuals with Type 1 DM have reduced pancreatic size in comparison with controls. Patients with Type 1 DM have increased echogenicity of the pancreas as the duration of the disease increased.

Keywords: Antero-posterior diameter, diabetes, echogenicity, pancreas

INTRODUCTION

The pancreas is a nonencapsulated vital organ, located in the anterior pararenal space of the retroperitoneum, posterior to the stomach.^[1] The pancreas is vulnerable to various morphological changes, including reduction in the pancreas dimensions caused by diabetes mellitus (DM), which may lead to the varying degrees of destruction and change in size of the pancreas.^[2]

The incidence of DM increased in all countries and both the rural and urban areas. In 2017, it was estimated that there are 451 million (age 18–99 years) people with DM worldwide.^[3] The illness places serious constraints on the patient's activities, especially when it is not well managed.^[4] The duration of DM affects both the lifespan and quality of life of the affected individual and may affect the morphology of the pancreas in different parts.

The ultrasound (US) plays an effective role to determine the pancreatic size since it is safe, cheap, and widely available.

The sensitivity and specificity of the US are high for evaluating the pancreatic tissue.^[5,6] In previous studies, the sonographic evaluation of the pancreas showed reduction in size in DM compared to controls.^[7] The early sonographic assessment of the pancreas may help to detect the morphological alterations which is essential for the diagnosis and management. The aim of this study is to evaluate the size and echotexture of the pancreas in relation with the duration of Type 1 DM.

MATERIALS AND METHODS

This is a cross-sectional, prospective, case-control study conducted during the period of March 2018–April 2019. The study targeted on assessment of 100 cases confirmed the diagnosis of Type 1 DM compared to 22 cases of healthy

Address for correspondence: Dr. Mohamed Adam Mohamed, Department of Radiological Sciences, College of Applied Medical Sciences, King Khalid University, Abha, Saudi Arabia. E-mail: madam@kku.edu.sa

Received: 18-06-2020 Revised: 25-07-2020 Accepted: 01-09-2020 Available Online: 30-01-2021

Access this article online

Quick Response Code:



Website:
www.jmuonline.org

DOI:
10.4103/JMU.JMU_89_20

This is an open access journal, and articles are distributed under the terms of the Creative Commons Attribution-NonCommercial-ShareAlike 4.0 License, which allows others to remix, tweak, and build upon the work non-commercially, as long as appropriate credit is given and the new creations are licensed under the identical terms.

For reprints contact: WKHLRPMedknow_reprints@wolterskluwer.com

How to cite this article: Abdulrahman S, Ibrahim AA, Mohamed MA, Gameraddin M, Alelyani M. Sonographic evaluation of the pancreas in type 1 diabetes mellitus: A case-control study. J Med Ultrasound 2021;29:167-70.

controls. The controls were defined as healthy asymptomatic children who had no pancreatic abnormalities or metabolic disorders. The exclusion criteria were participants who had any conditions or disorders affecting the pancreas, such as liver cirrhosis, thalassemia, pancreatitis, pancreatic tumors or cystic fibrosis, and all metabolic disorders. They were approximately similar to the case group in gender and age. The cases and controls were selected using the convenient sampling method. The study was approved from the Ethical Committee of Alzaiem Alzhari University and provided the number REC#11122017. Special consideration was given to the right confidentiality and anonymity of all research participants. Anonymity was achieved by using numbers for each research participant that would provide a link between the information collected and the participants. In addition, confidentiality was ensured by making the collected data accessible only to the researcher and the sonographer. Justice and human dignity were observed by treating selected patients equally when telling them to participate in the research as a sample of this study. The patients were free to decide whether to participate or not. Patient's data sheets were kept in a locked cabinet, and all the data were stored on a personal computer.

The sonographic procedure

The patients were fasting from food for at least 4 h to reduce the bowel and stomach gases anterior to the pancreas. Cups of water were given before the examination to enhance the visibility of the pancreas. The key landmarks for locating the pancreas in the upper abdominal longitudinal scan are the aorta, inferior vena cava, celiac trunk, superior mesenteric artery, and splenic vein. The left border of the abdominal aorta is used to mark the junction between the body and tail of the pancreas. The superior mesenteric artery and splenic vein were considered the important landmarks, for localization of the body of pancreas. The splenic vein was the main contributor for localizing the pancreatic tail.^[8] Transverse plane anterior approach with subxiphoid and a right subcostal scanning were applied to adjust for optimally visualizing the each part of the organ.

Coupling agent was added to confer acceptable acoustic contact among the transducer and the skin and further to allow sufficient transmission of the sound beam. In addition to transverse, longitudinal, and oblique scanning to delineate the pancreas, the spleen was also used as an acoustic window to assess the pancreatic tail. The interrogation was performed using left intercostal and subcostal coronal approaches, angle the heel of the transducer cephalad to the left hypochondriac region as the tail can be visualized nearby the hilum of the spleen. The diameters of head, body, and tail were determined and measured perpendicular to the long axis of the organ. Every part was measured three times and took the average as the final measurement.

The echogenicity of the pancreas was determined by comparison to the adjacent liver at a similar depth on both longitudinal and transverse views. Pancreatic echogenicity

was categorized as equal to, less than, or greater than liver echogenicity.^[9]

Statistical analysis

The data were analyzed using the SPSS software program (version 23, Chicago, IL, USA, IMB). Data were presented as mean \pm standard deviation independent *t*-test was used to compare between the cases and controls. The Chi-square test was used to find the association between echogenicity and duration of Type 1 DM. $P < 0.05$ was considered as statistically significant.

THE RESULTS

A total of 100 Sudanese affected by Type 1 DM were examined by ultrasound to assess the pancreatic measurements and echogenicity. They were compared to 22 healthy controls. The patients were 55 females and 45 males, whereas the controls were 8 males and 14 females. The mean age of patients with type 1-DM was 12.86 ± 2.91 years and 13.55 ± 3.69 years for the controls. The range of age was 6–15 years for type 1 DM and 6–14 years for the controls. The mean duration of the disease was 5.79 ± 2.64 years, and the range was 2–10 years, as shown in Table 1. There was no significant difference between cases and controls regarding the age and gender ($P = 0.343$, and 0.310), respectively. The body mass index (BMI) of patients with Type 1 DM was significantly increased higher than those of the controls (20.69 vs. 15.99 , $P = 0.001$), as shown in Table 1. The measurements of the pancreas are summarized in Table 2. The size of the head of the pancreas was higher in controls than diabetic patients without significant difference (1.80 vs. 1.78 , $P = 0.699$). According to Table 2, the size of the pancreatic body in controls is larger than diabetic patients (1.093 vs. 1.13 , $P = 0.484$). It was observed that the pancreatic tail is significantly bigger in controls than diabetic patients; (1.12 vs. 1.46 cm, $P < 0.001$), as shown in Table 2. Correlation of duration of Type 1DM with pancreatic size is summarized in Table 3. There was a negative significant correlation between pancreatic size and duration of DM. The size of pancreatic head and tail were significantly decreased as duration of Type 1 DM increased ($P = 0.048$ and 0.008 , respectively). However, the size of the pancreatic body showed no difference between the T1DM and control ($P = 0.3$). It was found the BMI has no significant association with the pancreatic echogenicity in the diabetic group ($P = 0.558$), as shown in Table 4.

Table 1: Demographic characteristics of the study sample

Variables	Type 1 DM	controls	P
Age (years), mean \pm SD	12.86 \pm 2.91	13.55 \pm 3.69	0.343
BMI, mean \pm SD	20.69 \pm 3.76	15.99 \pm 5.62	0.001
Duration of type 1 DM (years)	5.79 \pm 2.64		
Gender			
Males	45	8	0.310
Females	55	14	

SD: Standard deviation, DM: Diabetes mellitus, BMI: Body mass index

Table 2: Comparison of pancreatic measurements between type 1 diabetes mellitus and controls

Variables	Type 1 DM	controls	P	95% CI
AP diameter of pancreatic head (cm)	1.78±0.29	1.80±0.16	0.699	-147-0.099
AP diameter of pancreatic body (cm)	1.093±0.20	1.13±0.23	0.484	-2.97-1.196
AP diameter of pancreatic tail (cm)	1.12±0.25	1.46±0.54	<0.001	-491-0.194

AP: Antero-posterior, DM: Diabetes mellitus, CI: Confidence interval

Table 3: Correlation of duration of type 1 diabetes mellitus and pancreatic size

Variables	Correlation coefficient (r)	P
AP diameter of the head	-0.196	0.048
AP diameter of pancreatic body	0.105	0.30
AP diameter of tail of the pancreas	-0.264	0.008

AP: Antero-posterior

Table 4: Association of body mass index with echogenicity in the diabetic group

Statistical parameters	Value	Asymptotic significance (two-sided)
Pearson co-efficient	188.498	0.558
Likelihood ratio	197.689	0.374
Linear-by-linear association	0.533	0.465
Number of valid cases	100	

The echogenicity of the pancreas in Type 1 DM patients was significantly higher than those of the controls ($P = 0.015$), as demonstrated in Figure 1. It was shown that the echogenicity in diabetic patients was normal in 53 cases, hyperechoic in 25 cases, and hypoechoic in 22 cases, whereas in the controls, 19 cases showed normal echogenicity, 2 cases showed hypoechogenicity, and one case was hyperechoic [Figure 1].

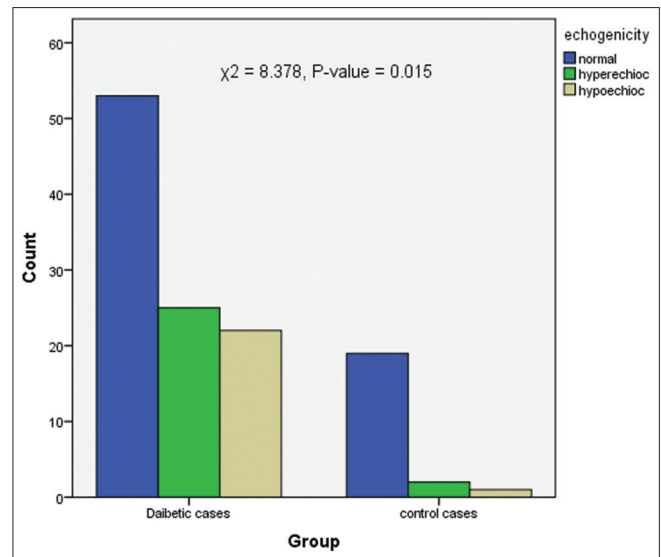
The association of echogenicity with duration of Type 1 DM is demonstrated in Figure 2. A significant association was found between duration of Type 1 DM and echogenicity ($P = 0.023$). Therefore, the echogenicity of pancreas increased significantly as the duration of the disease increased.

DISCUSSION

DM affects the size and echotexture of the pancreas. The disease causes severe complications and affects the patient's activities, especially when the disorder was not efficiently managed.^[10] Considering the effect of DM on the pancreas, the present study evaluated the alterations of the pancreas using ultrasonography.

The normal pancreatic dimensions showed considerable variation in the literature.^[11] In this study, the anteroposterior (AP) pancreatic diameters were examined and compared to the controls. Previous studies reported the different measures of AP diameters of pancreatic head, body, and tail.^[12,13]

The current study showed that the AP diameter of the head, body, and tail of the pancreas had decreased in the diabetic group

**Figure 1: Comparison of echogenicity of the pancreas in diabetic patients and controls**

compared to the controls. This was in consistency with Chavva and Karpur who studied the sonographic alterations of the pancreas in diabetic patients. They reported that the size of the pancreas was reduced in patients with type 1 DM.^[11] Agabi and Akhigbe reported that AP diameters of the head, body, and tail of the pancreas were smaller in diabetic patients than nondiabetic patients.^[12] Our findings were also approximately agreed with Raut *et al.*^[14] who found that the standard AP diameters were 1.18 ± 0.34 cm, 1.04 ± 0.23 cm, and 1.11 ± 0.25 cm for the head, body, and tail, respectively. They found that the tail of the pancreas is larger than the body, and this finding is similar to our result that the tail was larger than the body.

The study revealed that the duration of Type 1 DM has a significant impact on the pancreatic dimensions. Despite the negative weak correlation in our finding, it was found that the pancreatic head, body, and tail decreased as the duration of the illness increased. In contrast, Chavva and Karpur reported that the diameters of the pancreas had significant correlation with the duration of the disease.^[11] In addition, Agabi and Akhigbe reported that the longer the duration of diabetes, the smaller the sizes of body and tail of the pancreas.^[12] The significant reductions in the size of the pancreas might be attributed to microstructural changes and lack of insulin action which resulted in atrophy of the pancreas.^[13,15]

In addition, the current study showed increased pancreatic echogenicity in patients with Type 1 DM. It was observed

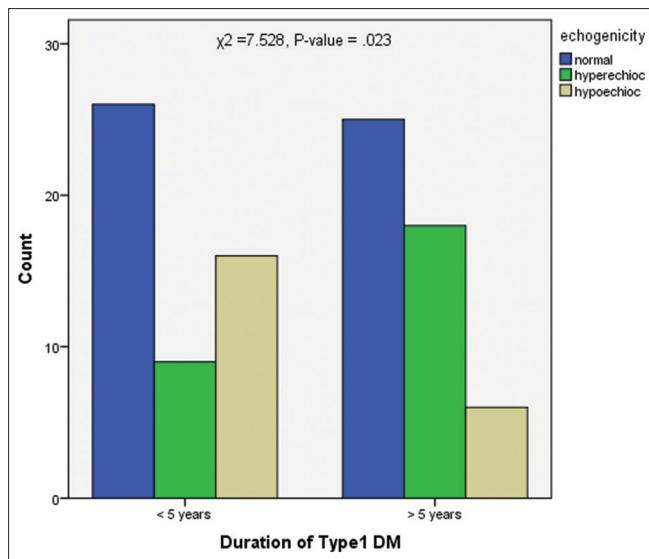


Figure 2: The association of duration of diabetes and echogenicity of the pancreas

that the echogenicity of pancreas increased as the duration of diabetes increased. Despite the BMI in our findings was higher in diabetic patients than the controls, it was found that there was no statistically significant correlation with the echogenicity ($P < 0.05$). In contrast, several studies have reported that increased echogenicity of the pancreas is attributed to lipomatosis which associated with increased BMI.^[16,17] In agreement to our results, Garcia *et al.*^[7] reported that patients with DM have increased fat content in the pancreas which in turn caused increased echogenicity. Furthermore, Hung *et al.* reported that the increased pancreatic echogenicity associated with deterioration of glycemic parameters.^[18] There was interaction or interference between the duration of DM and BMI. Therefore, the duration may affect the pancreatic echogenicity.

In light of the study findings, sonographic screening of pediatric diabetics is recommended for detection of early pancreatic morphological changes. However, we believed that the findings of decreased pancreas size along with increased echogenicity are essential and useful information that should be considered for the management of the pancreas in diabetic patients. An understanding of alterations of pancreas morphology and the duration of DM may lead to new insights in predicting, preventing complications, and treatment of the DM.

The present study faced some limitations since it is a single-center study and the sample size was not large enough. Some patients were excluded from the study because of bad preparations which cause excessive bowel gases that obstruct visualization of the pancreas.

CONCLUSION

Morphological alterations in the pancreas were observed in patients with Type 1 DM. In Type 1 DM, the AP diameters of

the head, body, and tail were reduced compared to nondiabetic patients. The echogenicity of the pancreas increased as the duration of the illness increased.

Financial support and sponsorship

Nil.

Conflicts of interest

There are no conflicts of interest.

REFERENCES

1. Sheik P. Retroperitoneum. In: Textbook of Radiology: Abdomen and Pelvis. New Delhi India: JP Medical Ltd.; 2018. p. 199.
2. Campbell-Thompson M, Rodriguez-Calvo T, Battaglia M. Abnormalities of the exocrine pancreas in type 1 diabetes. *Curr Diab Rep* 2015;15:79.
3. Cho NH, Shaw JE, Karuranga S, Huang Y, da Rocha Fernandes JD, Ohlrogge AW, *et al.* IDF diabetes atlas: Global estimates of diabetes prevalence for 2017 and projections for 2045. *Diabetes Res Clin Pract* 2018;138:271-81.
4. Adu MD, Malabu UH, Malau-Aduli AE, Malau-Aduli BS. Enablers and barriers to effective diabetes self-management: A multi-national investigation. *PLoS One* 2019;14:e0217771.
5. Kitano M, Yoshida T, Itonaga M, Tamura T, Hatamaru K, Yamashita Y. Impact of endoscopic ultrasonography on diagnosis of pancreatic cancer. *J Gastroenterol* 2019;54:19-32.
6. Sofuni A, Tsuchiya T, Itoi T. Ultrasound diagnosis of pancreatic solid tumors. *J Med Ultrasonics* 2020; 47:359-76.
7. Garcia TS, Rech TH, Leitão CB. Pancreatic size and fat content in diabetes: A systematic review and meta-analysis of imaging studies. *PLoS One* 2017;12:e0180911.
8. Talathi SS, Zimmerman R, Young M. Anatomy, Abdomen and Pelvis, Pancreas. In: StatPearls. Treasure Island (FL):StatPearls Publishing; January, 2020. Available from: <https://www.ncbi.nlm.nih.gov/books/NBK532912/>. [Last updated on 2020 Apr 15].
9. Choi CW, Kim GH, Kang DH, Kim HW, Kim DU, Heo J, *et al.* Associated factors for a hyperechoic pancreas on endoscopic ultrasound. *World J Gastroenterol* 2010;16:4329-34.
10. Makuc J. Management of pancreatogenic diabetes: Challenges and solutions. *Diabetes Metab Syndr Obes* 2016;9:311-5.
11. Chavva SP, Karpur SU. Ultrasonographic alterations of pancreas in diabetic patients. *Int J Contemp Med Surg Radiol* 2018;3:D160-2.
12. Agabi JO, Akhigbe AO. Comparative sonographic evaluation of the anteroposterior dimensions of the pancreas in diabetics and nondiabetics. *Niger J Clin Pract* 2016;19:175-81.
13. Virostko J, Himes MA, Williams JM, Wright J, Du L, Kang H, *et al.* Pancreas volume declines over the first year after diagnosis with type 1 diabetes (T1D). *Diabetes* 2016;67:42:248-57.
14. Raut DS, Raje DV, Dandge VP, Singh D. Percentile reference curves for normal pancreatic dimensions in Indian children. *Indian J Radiol Imaging* 2018;28:442-7.
15. Yagihashi S. Diabetes and pancreas size, does it matter? *J Diabetes Investig* 2017;8:413-5.
16. Al-Haddad M, Khashab M, Zyromski N, Pungpapong S, Wallace MB, Scolapio J, *et al.* Risk factors for hyperechoic pancreas on endoscopic ultrasound: A case-control study. *Pancreas* 2009;38:672-5.
17. Makino N, Shirahata N, Honda T, Ando Y, Matsuda A, Ikeda Y, *et al.* Pancreatic hyperechogenicity associated with hypoadiponectinemia and insulin resistance: A Japanese population study. *World J Hepatol* 2016;8:1452-8.
18. Hung CS, Tseng PH, Tu CH, Chen CC, Liao WC, Lee YC, *et al.* Increased pancreatic echogenicity with US: Relationship to glycemic progression and incident diabetes. *Radiology* 2018;287:853-63.